

The timing of language learning shapes brain structure associated with articulation

Jonathan A. Berken^{1,2} · Vincent L. Gracco^{2,3} · Jen-Kai Chen¹ · Denise Klein^{1,2}

Received: 20 March 2015 / Accepted: 22 September 2015
© Springer-Verlag Berlin Heidelberg 2015

Abstract We compared the brain structure of highly proficient simultaneous (two languages from birth) and sequential (second language after age 5) bilinguals, who differed only in their degree of native-like accent, to determine how the brain develops when a skill is acquired from birth versus later in life. For the simultaneous bilinguals, gray matter density was increased in the left putamen, as well as in the left posterior insula, right dorsolateral prefrontal cortex, and left and right occipital cortex. For the sequential bilinguals, gray matter density was increased in the bilateral premotor cortex. Sequential bilinguals with better accents also showed greater gray matter density in the left putamen, and in several additional brain regions important for sensorimotor integration and speech–motor control. Our findings suggest that second language learning results in enhanced brain structure of specific brain areas, which depends on whether two languages are learned simultaneously or sequentially, and on the extent to which native-like proficiency is acquired.

Keywords Bilingualism · Magnetic resonance imaging · Voxel-based morphometry · Gray matter density · Age of acquisition · Putamen · Motor cortex · Accent · Plasticity · Skill learning · Brain structure

Introduction

In recent years, neuroimaging has revealed how the brain is altered when a variety of specialized skills, ranging from taxi driving to musicianship and juggling, are acquired (Zatorre 2013; Maguire et al. 2006; Draganski et al. 2004). In these studies of experience-dependent plasticity, the structural and functional accommodations associated with the demands of learning have been explored in the mature, adult brain. How the brain wires when individuals acquire a skill from birth as compared to later in development, however, has not received significant attention to date. In this regard, bilingualism provides an optimal model for investigating such changes, since its acquisition can begin in early infancy or later during childhood or adulthood. Children raised from birth in a bilingual environment are able to become fully proficient in more than one language. Similarly, older children and adults are also able to master a second language (L2). Through the lens of bilingualism, therefore, we can examine differences in how the brain is shaped in response to early versus later life experience.

When learning a second language later in life, there appear to be limits to the capacity for acquiring native-like abilities (Flege et al. 1995). The persistence of accented speech in L2 has been attributed to age-related constraints on the plasticity of the motor and auditory systems (Moyer 2007; Penfield and Roberts 1959), and to the early adaptation of speech perception to sounds in the first language (L1; Kuhl 2010; Werker and Tees 1984). Most infants, for example, lose the ability to discriminate the phonemes of different languages by 6 months of age. In contrast, the window for phonological development remains open for an extended period of time when infants are exposed to two languages simultaneously (Werker and Tees 1984). While maturational constraints on acquiring other language

✉ Jonathan A. Berken
jonathan.berken@gmail.com

¹ Cognitive Neuroscience Unit, Montreal Neurological Institute, 3801 University Street, Room 264, Montreal, QC H3A 2B4, Canada

² Centre for Research on Brain, Language, and Music, McGill University, Montreal, QC H3G 2A8, Canada

³ Haskins Laboratories, New Haven, CT 06511, USA

subsystems, such as syntax and grammar, have also been well documented in both the behavioral (e.g., Weber-Fox and Neville 1996; Johnson and Newport 1989) and neuroimaging (e.g., Saur et al. 2009; Wartenburger et al. 2003) literature, they suggest a slower and more protracted trajectory that extends until puberty. For example, Johnson and Newport (1989) tested Korean and Chinese immigrants who arrived in the USA between 3 and 26 years of age and found a linear relationship between age and performance on a grammaticality judgment test that continued until age 12 years. The longer time course for syntactic than for phonological development makes sense given that syntactic rule learning depends on phonological cues (Hernandez and Li 2007; Christophe et al. 1997). In view of these different developmental trajectories, it is likely that L2 accent represents the speech domain most affected by non-native status and an important behavioral marker of early versus late experience-dependent neuroplasticity.

Functional neuroimaging studies of speech production of a late acquired L2 have identified the left putamen as a brain region reflecting the greater articulatory demands associated with speaking in a non-native language (Klein et al. 1994, 1995, 2006). Building on these functional brain imaging studies, Abutalebi et al. (2013) found increased gray matter density (GMD) in the left putamen of trilinguals who were highly proficient in an L1 and an L2, and moderately proficient in a third language (L3), an observation that the authors ascribed to the trilingual subjects' complex articulatory repertoire. However, the increased GMD in the left putamen might reflect the early acquisition of the first two languages, rather than the less proficient acquisition of a third language. In another study, Mechelli et al. (2004) found in a group of Italian speakers who acquired their L2, English, at ages ranging from 2 to 34 years, that gray matter density in the left inferior parietal region correlated negatively with age of L2 acquisition and positively with proficiency level. However, since it is unclear whether the early bilinguals were also those individuals with the highest bilingual proficiency, it is difficult to tease apart the precise contributions of these variables to the observed structural patterns.

The goal of the present study was to determine whether bilinguals who are able to achieve a high level of competence in an L2 later in life reveal structural patterns similar to early learners, or whether the structural differentiation of brain regions is limited by a sensitive period. Using voxel-based morphometry (VBM), a whole-brain anatomical magnetic resonance imaging (MRI) technique, we compared the brain structure of highly proficient simultaneous bilinguals (two languages acquired from birth) and sequential bilinguals (L2 learned after 5 years of age), who differed in accent ability. We hypothesized that differences in gray matter density would be observed in several brain

regions, particularly the left putamen and left prefrontal/premotor regions, which would relate to early versus late L2 acquisition, and to the degree of success that late bilinguals have in achieving native-like proficiency.

Materials and methods

Participants

Sixteen simultaneous bilinguals who acquired French and English from birth (10 females, age range 19–29 years, mean 23.3 years, standard deviation 3.1 years) and 18 sequential bilinguals who learned their L2 after the age of 5 years (8 females, age range 19–31 years, mean 25.7 years, standard deviation 4.5 years) participated in this study. Sequential bilinguals were either English (L1)–French (L2) or French (L1)–English (L2). We included these two combinations of language users in our sequential bilingual population, as we previously demonstrated that these orthographically similar languages are represented similarly in the brain for these participants (Berken et al. 2015). All bilingual subjects were exposed to and used French and English on a daily basis.

Participants were screened prior to scanning and were healthy, without hearing or reading impairment, neurological disorder, or history of brain trauma. Individuals who self-reported a high degree of musical skill or who received formal musical instruction were excluded, given the link between musical training and language ability (Schön et al. 2004) and the demonstrated plastic effects of musical experience on brain organization (Gaser and Schlaug 2003). Multilinguals, defined as individuals with any level of proficiency in any additional language acquired in any context, were also excluded. Equivalent non-verbal intelligence was determined between groups using the Block Design Subtest of the Wechsler Abbreviated Scale of Intelligence, $t(32) = 0.255$; $p = 0.801$ (WASI; see Table 1a; Wechsler 1981). Bilinguals were recruited from the McGill University community and gave informed consent. Testing procedures were approved by the Research Ethics Board of the Montreal Neurological Institute (MNI), Montreal, Quebec, Canada.

Assessment of language proficiency: self-report

A qualitative Language Experience and Proficiency Questionnaire (LEAP-Q; Marian 2007) was first administered. Simultaneous and sequential bilinguals reported a high level of proficiency in their two languages (see Table 1b). Subjects then rated their aptitude for learning languages, since this ability has been associated in the brain with distinct structural patterns (Golestani and Pallier 2007).

Table 1 Subject demographics and self-reported language assessment

	Simultaneous (<i>N</i> = 16)		Sequential (<i>N</i> = 18)	
(a) Subject background				
Gender				
Male/female	6/10		10/8	
Chronological age (years)	23.3 (3.1)		25.7 (4.5)	
L2 age of acquisition (years)	0 (0)		13.5 (6.4) ^a	
Formal education (years)	16.1 (2.7)		17.3 (3.1)	
WASI block design (1–19)	13.6 (1.6)		13.4 (2.4)	
	Simultaneous		Sequential	
	L1—French	L1—English	L1	L2
(b) Self-report: language assessment (LEAP-Q)				
% Exposure	37.3 (15.4)	60.5 (16.9)	62.2 (17.1)	37.3 (16.9)
Speaking ^b	8.9 (1.2)	9.1 (1.1)	9.4 (0.92)	7.5 (1.5)
Listening ^b	9.6 (0.62)	9.6 (0.89)	9.7 (0.67)	8.1 (1.3)
Reading ^b	9.4 (0.51)	9.6 (0.62)	9.6 (0.70)	7.9 (1.1)

Values are means (SD)

^a Range 5–26 years

^b 1 = Low proficiency, 10 = high proficiency

Subjects self-reported equivalent aptitude for language learning ($t(32) = 0.700$; $p = 0.490$).

Assessment of language proficiency: quantitative analysis of spontaneous speech

To quantify language proficiency, recordings of all bilingual subjects producing speech were obtained in French and English. Participants were asked to provide a spontaneous speech sample for 2 min in each language describing either a typical day at the beach or at the zoo. Instructions were delivered in the language required for the response. Subjects were instructed to create the most relevant story that came to mind. Spectrograms were generated for each sample using Praat software (Boersma 2001), and speech was then evaluated using the Compleat Lexical Tutor (Cobb 2009), an automated pipeline, for (a) lexicosemantics—number of unique and total words, (b) complexity of syntax, and (c) speech fluency—words per minute (Berken et al. 2015). Scoring by this algorithm was then checked for accuracy by manual inspection.

To establish an accent score for each subject in their two languages, three English and three French native speakers, unfamiliar with the objectives of the study, evaluated the recorded speech on a seven-point scale for the degree to which subjects sounded native-like (1—very poor/très faible, 7—native-like/langue maternelle). Results were assessed for interrater reliability in French and English ($\alpha = 0.92$ and 0.80 , respectively) and averaged across raters within each language, which provided accent scores for each subject in both languages.

Voxel-based morphometry

High-resolution T_1 -weighted images were acquired on a Siemens 3 Tesla scanner using a 3D magnetization prepared rapid gradient echo (MP-RAGE) sequence (TR = 2300 ms, TE = 2.98 ms, slice thickness = 1 mm isotropic, image matrix = 256×256 , flip angle = 9° , FOV = 256 mm, phase encode direction = A \rightarrow P, interleaved excitation, sagittal slice acquisition).

Magnetic resonance images were submitted to the CIVET pipeline (Ad-Dab'bagh et al. 2006), version 1.1.11, in-house software developed at the Montreal Neurological Institute. The T_1 -weighted images were corrected for intensity non-uniformity using a non-parametric non-uniform intensity normalization (N3) method (Sled et al. 1998). This technique minimizes low-frequency variation of signal intensity that arises from inhomogeneity in the electromagnetic field and radiofrequency reception coil and permits a more accurate tissue classification (Sled et al. 1998). The data analysis that followed normalization used unmodulated images, as recent literature suggests greater sensitivity and consistency across groups for this approach (Radua et al. 2014). The corrected images were then linearly registered into MNI152 standard space (Fonov et al. 2011) to reduce variability resulting from differences in head position, brain size, and brain shape, allowing for averaging across subjects. Registration from CIVET for each subject was then manually reviewed. Using an automatic classification algorithm known as INSECT (Intensity Normalized Stereotaxic Environment for the Classification of Tissue), individual voxels in each image were then

classified as gray matter, white matter, or cerebrospinal fluid (Collins et al. 1995). The three-dimensional gray matter maps created by the classification algorithm were subsequently blurred using an 8 mm isotropic Gaussian kernel in preparation for second-level analyses (Collins et al. 1994). No significant between-group differences were found for gray matter ($t(32) = 0.148$; $p = 0.883$), white matter ($t(32) = 0.209$; $p = 0.836$), cerebrospinal fluid ($t(32) = 0.603$; $p = 0.551$), or total intracranial volume (TIV; $t(32) = 0.121$; $p = 0.904$).

Several whole-brain analyses were carried out according to the general linear model. A two sample t test to contrast highly proficient simultaneous and sequential bilinguals was first performed to identify anatomical differences at the group level related to acquiring two languages from birth as compared to learning a second language later in life (i.e., the effects of age of acquisition). Chronological age, biological sex, and total intracranial volume were incorporated in the design as covariates of non-interest.

Given that the assessment of spontaneous speech revealed L2 accent score to be the only linguistic measure showing significant differences for sequential bilinguals, we next performed a regression analysis within this group to determine the neural correlates of accent proficiency in a non-native language. Simultaneous bilinguals were not included in this analysis, as they were homogenous with regard to accent score and demonstrated minimal inter-subject variability. Chronological age, biological sex, total intracranial volume, age of acquisition, as well as the other linguistic factors from the analysis of spontaneous speech (i.e., syntax, vocabulary, speech rate) were included in the design model as covariates.

Gray matter t -statistical maps were generated and voxels that survived a threshold corresponding to $p < 0.001$ uncorrected, using random field theory (Worsley et al. 1996) were deemed significant. Brain regions that revealed differences in gray matter density were identified by comparison with the Talairach atlas (Talairach and Tournoux 1988).

Results

Quantitative language assessment

Simultaneous and sequential bilinguals were highly proficient in both languages, although sequential bilinguals produced speech with a more native-like accent in their L1 than L2 ($t(34) = 4.56$; $p = 0.0001$). Simultaneous bilinguals' speech in French and English was also significantly more native sounding than the sequential bilinguals' speech in L2 ($t(32) = 3.67$; $p = 0.009$; $t(32) = 2.47$; $p = 0.019$, respectively). No other significant within- or

between-group behavioral difference was noted (see Table 2). For the sequential bilinguals, accent did not correlate significantly with age of acquisition ($R = -0.179$, $p = 0.477$), nor with the other linguistic factors evaluated from the spontaneous speech samples, $p > 0.05$. However, accent did correlate significantly with self-reported speaking score ($R = 0.602$, $p = 0.008$) and reading score ($R = 0.640$, $p = 0.004$) from the Language Experience and Proficiency Questionnaire.

Group VBM comparison: simultaneous > sequential bilinguals

Simultaneous bilinguals, when compared with sequential bilinguals, revealed significantly greater gray matter density in the left putamen, left posterior insular cortex, left mid-occipital gyrus, right dorsolateral prefrontal cortex, and right lateral occipital cortex (Fig. 1a; Table 3).

Group VBM comparison: sequential > simultaneous bilinguals

Significantly greater GMD was observed for sequential bilinguals compared to simultaneous bilinguals in the bilateral premotor cortex (Fig. 1b; Table 3).

VBM regression analysis in sequential bilinguals

A significant positive correlation between accent score and gray matter density was observed in the sequential bilingual group, when chronological age, biological sex, total intracranial volume, age of acquisition, as well as the other linguistic measures from the spontaneous speech assessment, were included in the GLM as covariates. Here, the more native-like the L2 accent, the greater was the GMD in the left putamen. Overlap between the left putamen peaks from both the group comparison and this regression analysis with accent score occurred at the coordinates $x = -23$, $y = 3$, $z = -7$.

The left inferior frontal gyrus, left premotor cortex, left cerebellar vermis, right primary motor cortex, right Heschl's gyrus, right lateral occipital cortex, and bilateral inferior parietal lobule (IPL) also significantly and positively correlated with accent score (Fig. 2; Table 4).

Discussion

In the present study, we contrasted highly proficient simultaneous and sequential bilinguals using voxel-based morphometry to identify differences in brain structure that occur when two languages are acquired from birth and when a second language is learned to a high degree of

Table 2 Analysis of spontaneous speech

	Simultaneous		Sequential	
	L1—French	L1—English	L1	L2
Lexicosemantics				
No. of unique words	130.0 (22.4)	134.3 (15.2)	134.7 (24.6)	113.4 (27.2)
No. of total words	310.5 (71.6)	304.4 (41.8)	313.4 (59.4)	265.2 (64.9)
Syntax				
% Complex sentences	36.3 (14.7)	40.2 (14.8)	39.3 (20.1)	37.4 (15.9)
Speech fluency				
Words per minute	155.1 (35.9)	152.2 (20.9)	156.7 (29.7)	132.6 (32.4)
Phonology				
Accent (rating 1–7)	5.4 (1.1)	5.8 (0.88)	6.1 (0.87)	4.3 (1.3)*

Values are means (SD)

* Denotes significance of $p < 0.05$

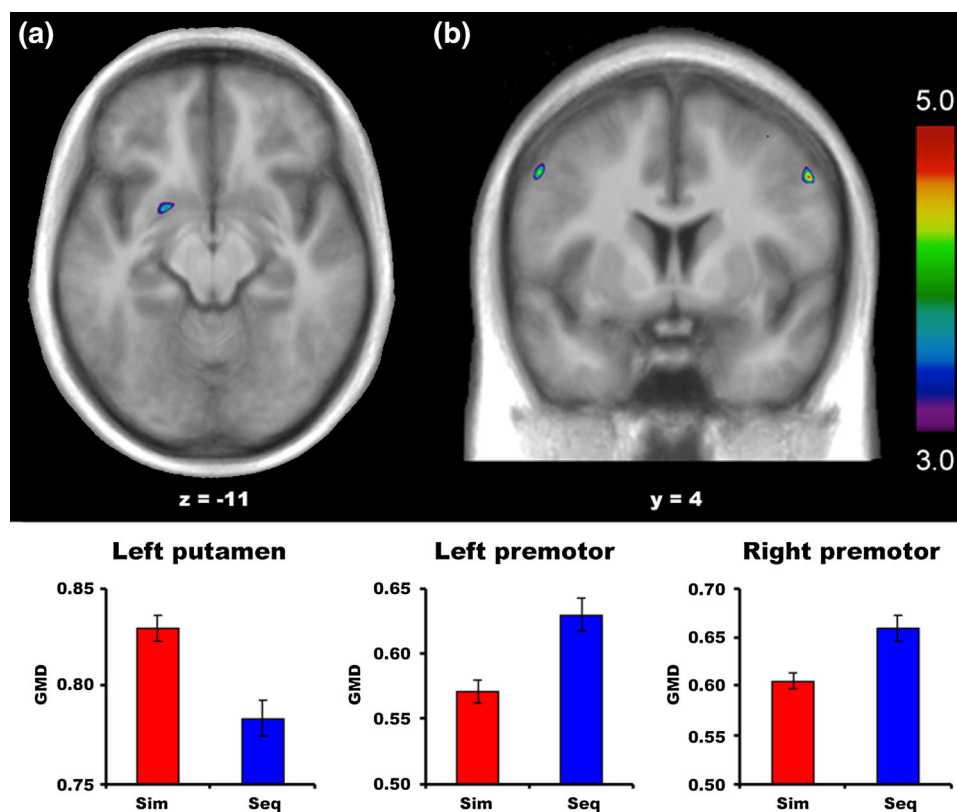


Fig. 1 t-Maps representing simultaneous and sequential bilingual group contrasts. Brain areas demonstrating significant differences in gray matter density are projected onto the average anatomical MR image of all bilingual subjects. **a** Simultaneous bilinguals demonstrated greater GMD relative to sequential bilinguals in the left putamen (pictured above), left posterior insula, left mid-occipital gyrus, right dorsolateral prefrontal cortex, and right lateral occipital

cortex. In contrast, **b** sequential bilinguals revealed greater GMD only in the bilateral premotor cortex (pictured above). For both **a** and **b**, bar charts indicate GMD averaged over the group at the peak voxel, with error bars representing standard error of the mean. The left hemisphere is on the left in all images. For voxel-wise threshold corresponding to $p < 0.001$, uncorrected significance was established according to random field theory (Worsley et al. 1996)

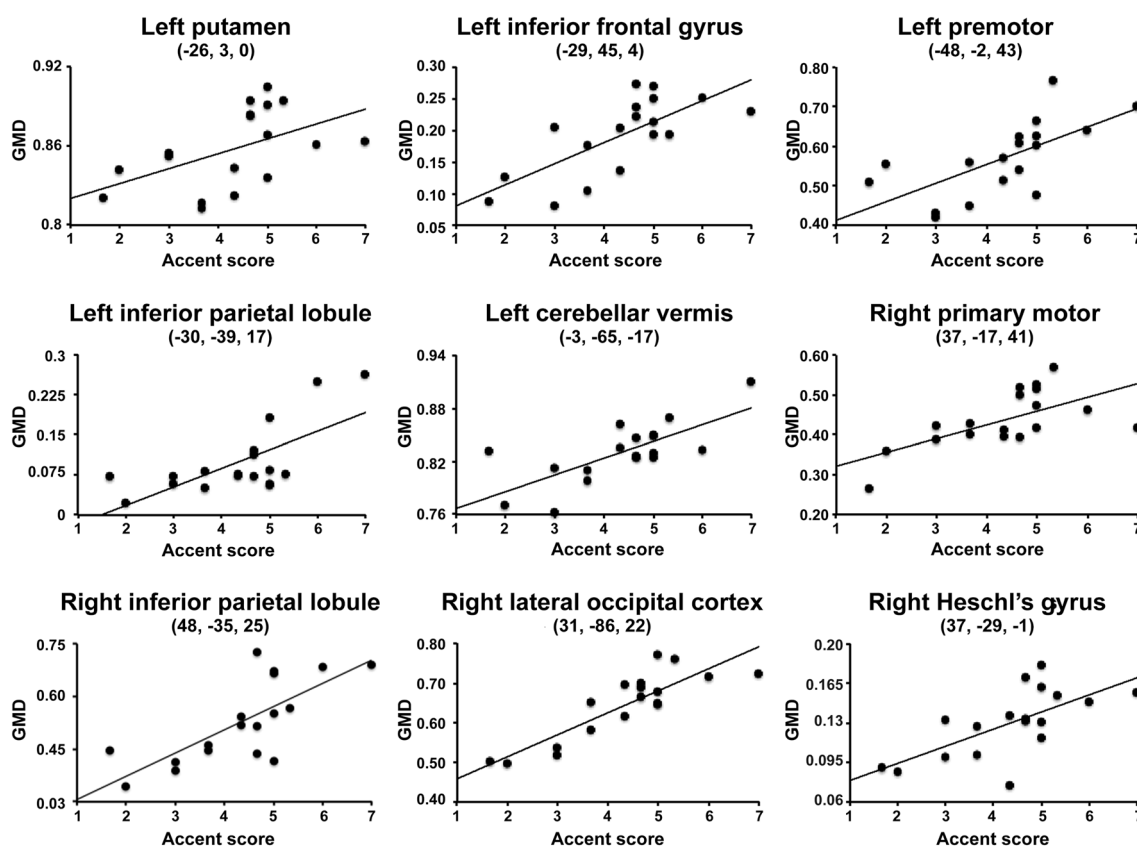
proficiency later in life. Native acquisition of two languages resulted in increased GMD in the left putamen, as well as in prefrontal, insular, and occipital cortices. In contrast, later L2 acquisition resulted in denser gray matter

only in the bilateral premotor cortex. For sequential bilinguals, however, higher L2 accent ability was associated with increased GMD in a number of brain regions that included the left putamen, as well as additional brain areas

Table 3 Group contrast of simultaneous and sequential bilinguals

Brain area	<i>x, y, z</i>	<i>t</i>	<i>p</i>	Volume (mm ³)
Simultaneous > sequential				
Left hemisphere				
Putamen	-21, 5, -11	4.0	<0.001	88
Posterior insula, BA 13	-37, -7, -1	3.9	<0.001	151
Mid-occipital gyrus, BA 18	-18, -92, 15	4.8	<0.001	282
Right hemisphere				
Dorsolateral prefrontal cortex, BA 45	40, 29, 29	5.2	<0.001	295
Occipital cortex, BA 17	20, -97, 1	4.5	<0.001	175
Sequential > simultaneous				
Left hemisphere				
Premotor cortex, BA 6	-54, 1, 41	4.9	<0.001	147
Right hemisphere				
Premotor cortex, BA 6	53, 5, 40	4.9	<0.001	101

Peak MNI coordinates

**Fig. 2** Regression analysis in sequential bilinguals: accent. A positive correlation between accent score (1 = very poor, 7 = native-like) and gray matter density was observed in the sequential bilingual group, when chronological age, biological sex, total intracranial volume, age of acquisition, as well as the other linguistic measures from the spontaneous speech assessment, were included in

the GLM as covariates. Here, the more native-like was the L2 accent, the greater was the GMD in the left putamen, left inferior frontal gyrus, left premotor cortex, left cerebellar vermis, right primary motor cortex, right Heschl's gyrus, bilateral inferior parietal lobule, and right occipital cortex. *Scatter plots* indicate relationship between GMD of peak voxel in cluster and accent score

involved in sensorimotor integration and articulatory planning. Overall, while the present findings suggest that achieving bilingual proficiency, whether early or later in

life, involves denser gray matter within the left putamen, they also point to increased GMD in brain regions involved in sensorimotor learning and speech-motor control that

Table 4 Regression analysis in sequential bilinguals: positive correlation with L2 accent

Brain area	<i>x, y, z</i>	<i>r</i>	<i>p</i>	Volume (mm ³)
Left hemisphere				
Putamen	−26, 3, 0	0.51	<0.001	76
Inferior frontal gyrus	−29, 45, 4	0.72	<0.001	75
Premotor cortex, BA 6	−48, −2, 43	0.63	<0.001	312
Inferior parietal lobule, BA 40	−30, −39, 17	0.70	<0.001	192
Cerebellum (vermis)	−3, −65, −17	0.73	<0.001	239
Right hemisphere				
Primary motor cortex, BA 4	37, −17, 41	0.63	<0.001	28
Primary auditory cortex/Heschl's gyrus, BA 21	37, −29, −1	0.57	<0.001	851
Inferior parietal lobule, BA 40	48, −35, 25	0.74	<0.001	712
Occipital cortex, BA 18	31, −86, 22	0.86	<0.001	340

Peak MNI coordinates

might serve as compensatory mechanisms for sequential bilinguals to approximate native-like articulation.

Simultaneous bilingual acquisition

Simultaneous bilinguals evidenced increased GMD in the left putamen compared to sequential bilinguals. The left putamen has been identified as a subcortical structure playing a key role in language production, especially in motor programming and articulatory coding (Booth et al. 2008; Marchand et al. 2008). Previous research has reported increased activation of the left putamen in late bilinguals during L2 speech production, an observation taken to reflect the complex articulatory demands imposed by speaking in a non-native language (Abutalebi et al. 2013; Klein et al. 2006; Frenck-Mestre et al. 2005; Klein et al. 1994, 1995). Damage to the putamen has been associated with foreign accent syndrome, a disorder characterized by speech patterns that simulate the phonology of a non-native language (Kurowski et al. 1996).

Similar to the present results, increased GMD in trilingual speakers who were highly proficient in two languages, and moderately proficient in a third, was found in the left putamen (Abutalebi et al. 2013). While the authors attributed their finding to the rich phonetic inventory of the trilingual speakers, it was unclear whether proficiency was modulating the structural difference or whether it was the early acquisition of the trilinguals' first two languages that resulted in this enhancement. The present results suggest that increased GMD in the left putamen is an effect of acquiring two languages from birth that facilitates native-sounding speech. Interestingly, the correlation with accent in the highly proficient sequential bilinguals suggests that this structure is important for native-like articulation, whether the second language is acquired early or later in development.

Simultaneous bilingual acquisition also resulted in enhanced GMD in the left posterior insula, a cortical region that is functionally connected to the left putamen (Postuma and Dagher 2006). The posterior insula appears to be involved in sensorimotor integration and may facilitate speech-related feedback, fine-tuning speech–motor output in coordination with the left putamen, resulting in more native-like pronunciation.

Significantly greater GMD was also observed for simultaneous bilinguals in the right dorsolateral prefrontal cortex, a finding consistent with the behavioral and imaging literature on language control requirements in bilinguals (for a review see Hervais-Adelman et al. 2011) and particularly with the reports of an executive control advantage in early bilinguals (e.g., Luk et al. 2011). Although development of the dorsolateral prefrontal cortex extends into early adulthood, evidence suggests that significant maturational changes occur rapidly during the first year of life to promote cognitive processes, including language acquisition (Sowell et al. 2004). It is also likely that the dorsolateral prefrontal cortex plays a role in managing speech production, perhaps by suppressing competing language inputs (Green 1998).

Finally, dual language acquisition from birth also appears to alter brain structures that support secondary linguistic skills, such as reading. In particular, we found that the mid-occipital gyrus and lateral occipital cortex demonstrated greater GMD in simultaneous bilinguals. These brain regions have been shown to relate to reading ability (He et al. 2013) that in turn depends on phonological awareness (Goswami 2008) and, therefore, is influenced by early experience. These findings suggest that the wiring of the neural circuits for speech is optimized when language is learned early (Moyer 2007; Penfield and Roberts 1959), thus facilitating the development of native-like skill in speech production in the two languages.

Sequential bilingual acquisition

In contrast, sequential bilinguals demonstrated denser gray matter in the bilateral premotor cortex, an area associated with heightened functional activation during L2 speech production (Berken et al. 2015). The premotor cortex is known to be involved in motor learning (Dayan and Cohen 2011), and increased cortical thickness and GMD in the right hemisphere have been associated with musicianship (Bermudez et al. 2008) and musical skill acquisition in children after 15 months of training (Hyde et al. 2009). It appears that increased GMD in the bilateral premotor cortex is related to the later (after a sensitive period) acquisition of a second language. Moreover, other evidence of increased GMD in different portions of the premotor cortex across a number of skilled behaviors acquired post-development (Gerber et al. 2014; Schlaffke et al. 2014) highlights the domain general nature of the ventral premotor cortex.

In addition to the left putamen, the GMD of several brain regions related to sensorimotor integration and speech–motor control, including the left inferior frontal gyrus, left premotor cortex, left cerebellar vermis, right primary motor cortex, and bilateral inferior parietal lobule, correlated with speech production proficiency for sequential bilinguals. In a recent study, Reiterer et al. (2011) examined individual differences in audio-vocal imitation and found enhanced gray matter volume and reduced hemodynamic activation within the fronto-parietal network for late bilinguals with a talent for speech imitation. The inferior parietal lobule, an important component of this network, has also been shown to impact sensorimotor integration and sensorimotor learning for speech (Shum et al. 2011). In fact, the IPL emerged in a study by Mechelli et al. (2004) as a region of increased GMD in more proficient bilinguals, although accent was not a proficiency criterion assessed in their investigation. These same brain regions were again noted in a study by Golestani and Pallier (2007), who, using a longitudinal paradigm, observed a positive relationship between speech-sound production learning and brain structure within inferior prefrontal regions and the inferior parietal lobule. Interestingly, Golestani and Zatorre (2004) also found a functional correspondence between successful perception of a difficult Hindi dental-retroflex contrast and activation in anterior frontal areas, suggesting that these regions serve both production and perception. While, in the current study, we report variability in L2 accent production skill, it is also likely, given what is known about the early closing of the window for phonological development, that individual differences exist at the perceptual level as well. In this regard, the observed GMD differences found in sequential bilinguals, including that noted in the IFG, might also reflect heterogeneity among late bilingual subjects in phonological perception, though this was not tested here.

In this same vein, greater density within Heschl's gyrus, a key structure implicated in auditory and linguistic processing (Ressel et al. 2012; Golestani et al. 2007), was also associated with higher accent ability. Again, it is possible that this finding reflects perceptual differences among the sequential bilingual group that consequently affects production skill. Nevertheless, it seems that learning a second language after an early perceptual window has closed holds important implications for neuroplasticity that promotes the production of native-like accent. These results shed light on the neural structures implicated in achieving automaticity in bilingual speech production, and the sensorimotor integration and speech–motor control required when second language learning occurs after a developmentally sensitive period. It is important to note that the greater GMD of these brain regions correlated only with accent score, and not with the other linguistic measures from the assessment of spontaneous speech production (i.e., lexicosemantics, syntax, speech rate), as the model used for the regression analysis with accent included these variables as covariates. Further, we report differences related to gray matter density, but it is likely that there are concomitant alterations in white matter in a given brain structure. This can result in a degree of partial volume effect, a phenomenon that occurs in areas when both gray and white matter co-exist in close proximity. The VBM results likely contain contributions from both, and the correspondence between the VBM values and the microanatomical structure that underlies them is uncertain. Thus, while VBM is useful for exploring the brain at the macrostructural level, it is not informative about the microscopic molecular, cellular, and biochemical factors driving our findings.

A sensitive period for skill acquisition

The differences in brain structure for the simultaneous and sequential bilinguals parallel the types of changes observed in other sensorimotor domains, when development begins at different points during an individual's lifetime. For example, deaf children who receive cochlear implants during a brief optimal period that spans their first few postnatal years experience reorganization of cortical auditory areas that correlates with the ultimate effectiveness of the implant (Giraud and Lee 2007). However, the performance of children receiving implants later in life varies greatly because significant cross-modal neuroplastic changes have already occurred in varying degrees (Buckley and Tobey 2011). Those who do well activate dorsolateral prefrontal networks involved with attention control and working memory, while those who do poorly show evidence of auditory cortex activation in visual processing (Giraud and Lee 2007), suggesting that the pattern of brain

plasticity may be important in compensating for late-acquired abilities. For sequential bilinguals, individual differences in accent quality are likely the result of a process analogous to that of children receiving cochlear implants after an optimal period. That is, the variability in accent skill observed in late bilinguals may reflect limitations in the potential for structural and functional modification of cortical and subcortical structures to approximate native-like speech, in view of the early closure of the optimal period for phonological development.

The structural patterns observed in this VBM study, together with results from a previous fMRI investigation of speech production in these same subjects (Berken et al. 2015), shed light on the relationship between brain structure and function, a topic of considerable recent interest. Our findings suggest that while early, simultaneous language acquisition leads to increased GMD in specific brain areas, resulting in less intense hemodynamic activation, late L2 acquisition requires the structural enhancement of alternative and additional neural regions, as well as increased functional recruitment of these areas to achieve native-like speech. Future neuroimaging investigations using longitudinal designs should help disentangle causal relationships between native-like articulatory proficiency and brain maturation, as it is yet undetermined whether late L2 learners with better accents are born predisposed to greater development of specific brain regions important for articulation (e.g., the left putamen) or whether their brains are more plastic during learning. Nevertheless, the present study suggests that neuroplastic changes related to second language experience differ depending on whether language acquisition occurs very early in life or at a later time.

Acknowledgments Jennifer Soles assisted with the experimental setup and subject recruitment. Megan Callahan assisted with the quantitative language assessment. The study was supported by funds from the Blema and Arnold Steinberg Family Foundation and grants from the Natural Sciences and Engineering Research Council of Canada (NSERC) to D. Klein and V. Gracco, the Social Sciences and Humanities Research Council of Canada (SSHRC) to Baum, Gracco, and Klein, and a Vanier Canada Doctoral Scholarship to J. Berken (NSERC).

Compliance with ethical standards

Conflict of interest The authors declare no competing financial interests.

References

- Abutalebi J, Della Rosa PA, Gonzaga AK, Keim R, Costa A, Perani D (2013) The role of the left putamen in multilingual language production. *Brain Lang* 125(3):307–313
- Ad-Dab'bagh Y, Einarson D, Lyttelton O, Muehlboeck J-S, Mok K, Ivanov O, Vincent RD, Lepage C, Lerch J, Fombonne E, Evans AC (2006) The CIVET image-processing environment: a fully automated comprehensive pipeline for anatomical neuroimaging research. In: Corbetta M (ed) Proceedings of the 12th annual meeting of the organization for human brain mapping. NeuroImage, Florence. <http://www.bic.mni.mcgill.ca/users/yaddab/Yasser-HBM2006-Poster.pdf>
- Berken JA, Gracco VL, Chen J-K, Watkins KE, Baum SM, Callahan M, Klein D (2015) Neural activation in speech production and reading aloud in native and non-native languages. *NeuroImage* 112:208–217
- Bermudez P, Lerch JP, Evans AC, Zatorre RJ (2008) Neuroanatomical correlates of musicianship as revealed by cortical thickness and voxel-based morphometry. *Cereb Cortex* 19:1583–1596
- Boersma P (2001) Praat, a system for doing phonetics by computer. *Glott Int* 5(9/10):341–345
- Booth JR, Mehdiratta N, Burman DD, Bitan T (2008) Developmental increases in effective connectivity to brain regions involved in phonological processing during tasks with orthographic demands. *Brain Res* 1189:78–89
- Buckley KA, Tobey EA (2011) Cross-modal plasticity and speech perception in pre- and postlingually deaf cochlear implant users. *Ear Hear* 32(1):2–15. doi:10.1097/AUD.0b013e3181e8534c
- Cobb T (2009) The compleat lexical tutor. <http://www.lex tutor.ca>. Accessed 18 Sep 2012
- Christophe A, Guasti T, Nespore M, Dupoux E, Van Ooyen B (1997) Reflections on phonological bootstrapping: its role for lexical and syntactic acquisition. *Lang Cogn Proc* 12:585–612. doi:10.1080/016909697386637
- Collins DL, Neelin P, Peters TM, Evans AC (1994) Automatic 3D intersubject registration of MR volumetric data in standardized Talairach space. *J Comput Assist Tomogr* 18:192–205
- Collins D, Holmes C, Peters T, Evans AC (1995) Automatic 3D model-based neuroanatomical segmentation. *Hum Brain Mapp* 3(3):190–208
- Dayan E, Cohen LG (2011) Neuroplasticity subserving motor skill learning. *Neuron* 72:443–454
- Draganski B, Draganski B, Gaser C, Busch V, Schuierer G, Bogdahn U, May A (2004) Neuroplasticity: changes in grey matter induced by training. *Nature* 427(6972):311–312
- Flege JE, Munro MJ, MacKay IRA (1995) Factors affecting strength of perceived foreign accent in a second language. *J Acoust Soc Am* 97:3125–3134
- Fonov V, Evans AC, Botteron K, Almli CR, McKinnstry RC, Collins DL, Brain Development Cooperative Group (2011) Unbiased average age-appropriate atlases for pediatric studies. *NeuroImage* 54(1):313–327
- Frenck-Mestre C, Anton JL, Roth M, Vaid J, Viallet F (2005) Articulation in early and late bilinguals' two languages: evidence from functional magnetic resonance imaging. *NeuroReport* 7:761–765
- Gaser C, Schlaug G (2003) Gray matter differences between musicians and nonmusicians. *Ann N Y Acad Sci* 999:514–517
- Gerber P, Schlaffke L, Heba S, Greenlee MW, Schultz T, Schmidt-Wilcke T (2014) Juggling revisited: a voxel-based morphometry study with expert jugglers. *NeuroImage* 95:320–325
- Giraud AL, Lee HJ (2007) Predicting cochlear implant outcome from brain organisation in the deaf. *Restor Neurol Neurosci* 25:381–390
- Golestani N, Pallier C (2007) Anatomical correlates of foreign speech sound production. *Cereb Cortex* 17(4):929–934
- Golestani N, Zatorre RJ (2004) Learning new sounds of speech: reallocation of neural substrates. *NeuroImage* 21(2):494–506
- Golestani N, Molko N, Dehaene S, LeBihan D, Pallier C (2007) Brain structure predicts learning of foreign speech sounds. *Cereb Cortex* 17(3):575–582
- Goswami U (2008) The development of reading across languages. *Ann N Y Acad Sci* 1145:1–12

- Green DW (1998) Mental control of the bilingual lexico-semantic system. *Biling Lang Cognit* 1:67–81
- He Q et al (2013) Decoding the neuroanatomic basis of reading ability. *J Neurosci* 33(31):12835–12843
- Hernandez AE, Li P (2007) Age of acquisition: its neural and computational mechanisms. *Psychol Bull* 133(4):638–650
- Hervais-Adelman AG, Moser-Mercer B, Golestani N (2011) Executive control of language in the bilingual brain: integrating the evidence from neuroimaging to neuropsychology. *Front Psychol* 2:234. doi:10.3389/fpsyg.2011.00234 (eCollection 2011)
- Hyde K, Lerch J, Norton A, Forgeard M, Winner E, Evans AC, Schlaug G (2009) Musical training shapes structural brain development. *J Neurosci* 29(10):3019–3025
- Johnson JS, Newport EL (1989) Critical period effects in second language learning: the influence of maturational state on the acquisition of English as a second language. *Cogn Psychol* 21(1):60–99
- Klein D, Zatorre RJ, Milner B, Meyer E, Evans AC (1994) Left putaminal activation when speaking a second language: evidence from PET. *NeuroReport* 5:2295–2297
- Klein D, Milner B, Zatorre RJ, Meyer E, Evans AC (1995) The neural substrates underlying word generation: a bilingual functional-imaging study. *Proc Natl Acad Sci USA* 92(7):2899–2903
- Klein D, Watkins KE, Zatorre RJ, Milner B (2006) Word and nonword repetition in bilingual subjects: a PET study. *Hum Brain Mapp* 27:153–161
- Kuhl PK (2010) Brain mechanisms in early language acquisition. *Neuron* 65(7):713–727
- Kurowski KM, Blumstein SE, Alexander M (1996) The foreign accent syndrome: a reconsideration. *Brain Lang* 54(1):1–25
- Luk G, Bialystok E, Craik FI, Grady CL (2011) Lifelong bilingualism maintains white matter integrity in older adults. *J Neurosci* 31(46):16808–16813
- Maguire EA, Woollett K, Spiers HJ (2006) London taxi drivers and bus drivers: a structural MRI and neuropsychological analysis. *Hippocampus* 16(12):1091–1101
- Marchand WR, Lee JN, Thatcher JW, Hsu EW, Rashkin E, Suchy Y, Chelune G, Starr J, Barbera SS (2008) Putamen coactivation during motor task execution. *NeuroReport* 19(9):957–960
- Marian V (2007) The Language Experience and Proficiency Questionnaire (LEAP-Q): assessing language profiles in bilinguals and multilinguals. *J Speech Lang Hear Res* 50(4):940–967
- Mechelli A, Crinion JT, Noppeney U, O’Doherty J, Ashburner J, Frackowiak RS, Price CJ (2004) Neurolinguistics: structural plasticity in the bilingual brain. *Nature* 431:757
- Moyer A (2007) Empirical consideration on the age factor in L2 phonology. *Issues Appl Ling* 15(2):109–127
- Penfield W, Roberts L (1959) *speech and brain mechanisms*. Athenaeum, New York
- Postuma RB, Dagher A (2006) Basal ganglia functional connectivity based on a meta-analysis of 126 positron emission tomography and functional magnetic resonance imaging publications. *Cereb Cortex* 16(10):1508–1521
- Radua J, Canales-Rodriguez ES, Pomerol-Clotet E, Salvador R (2014) Validity of modulation and optimal setting for advanced voxel-based morphometry. *NeuroImage* 86:81–90
- Reiterer SM, Hu X, Erb M, Rota G, Nardo D, Grodd W, Winkler S, Ackermann H (2011) Individual differences in audio-vocal speech imitation aptitude in late bilinguals: functional neuroimaging and brain morphology. *Front Psychol* 2:271. doi:10.3389/fpsyg.2011.00271 (eCollection 2011)
- Ressel V, Pallier C, Ventura-Campos N, Díaz B, Roessler A, Ávila C, Sebastián-Gallés N (2012) An effect of bilingualism on the auditory cortex. *J Neurosci* 32(47):16597–16601
- Saur D, Baumgaertner A, Moehring A, Büchel C, Bonnesen M, Rose M, Musso M, Meisel JM (2009) Word order processing in the bilingual brain. *Neuropsychologia* 47(1):158–168
- Schlaffke L, Lissek S, Lenz M, Brüne M, Juckel G, Hinrichs T, Platen P, Tegenthoff M, Schmidt-Wilcke T (2014) Sports and brain morphology—a voxel-based morphometry study with endurance athletes and martial arts. *Neuroscience* 259:35–42
- Schön D, Magne C, Besson M (2004) The music of speech: music training facilitates pitch in both music and language. *Psychophysiology* 41(3):3410349
- Shum M, Shiller DM, Baum SR, Gracco VL (2011) Sensorimotor integration for speech motor learning involves the inferior parietal cortex. *Eur J Neurosci* 34(11):1817–1822
- Sled JG, Zijdenbos AP, Evans AC (1998) A nonparametric method for automatic correction of intensity nonuniformity in MRI data. *IEEE Trans Med Imaging* 17(1):87–97
- Sowell ER, Thompson PM, Toga AW (2004) Mapping changes in the human cortex throughout the span of life. *Neuroscientist* 10(4):372–392
- Talairach J, Tournoux P (1988) *Co-planar stereotaxic atlas of the human brain*. Thieme Medical, New York
- Wartenburger I, Heekeren HR, Abutalebi J, Cappa SF, Villringer A, Perani D (2003) Early setting of grammatical processing in the bilingual brain. *Neuron* 37(1):159–170
- Weber-Fox CM, Neville HJ (1996) Maturation constraints on functional specializations for language processing: ERP and behavioral evidence in bilingual speakers. *J Cogn Neurosci* 8(3):231–236
- Wechsler D (1981) *Manual for the Wechsler Adult Intelligence Scale—revised*. The Psychological Corporation, San Antonio
- Werker JF, Tees RC (1984) Phonemic and phonetic factors in adult cross-language speech perception. *J Acoust Soc Am* 75(6):1867–1878
- Worsley KJ, Marrett S, Neelin P, Vandal AC, Friston KJ, Evans AC (1996) A unified statistical approach for determining significant signals in images of cerebral activation. *Hum Brain Mapp* 4(1):58–73
- Zatorre RJ (2013) Predispositions and plasticity in music and speech learning: neural correlates and implications. *Science* 342(6158):585–589